


**PATIENT**

Pudding Horky

**SPECIES**

Feline

**BREED**

DSH

**SEX**

Male Neutered

**AGE**

13.6 years

**WEIGHT**

12.4lbs

**INTERPRETED BY**

 Maggie Machen Lamy,  
 DVM, DACVIM  
 (Cardiology)

**IMAGING PERFORMED BY**

 Potomac Mobile  
 Veterinary Ultrasound

**HOSPITAL NAME**

 Kindness Animal  
 Hospital

**REFERRING VET**

Dr. Jarrett

**INVOICE**

26802

**DATE**

10/10/22

**PRESENTING CLINICAL SIGNS**

History: Tumor in right cranial chest. Vomiting daily, weight loss, pulmonary mass, grade 3/6 heart murmur, occasional skipped heartbeat, and body condition score is 6/9. Assess prior to institution of steroids.

Abnormal PE/Chem/CBC/UA Results: (07/13/2022) CHEM/CBC: NSF. T4: WNL. UPC: 0.1. ProBNP: 163.

**ECHOCARDIOGRAM FINDINGS**

2D, m-mode, color flow and doppler imaging is available. The left ventricular wall thickness is mildly increased with regions of irregularity. There is a diffusely hyperechoic endocardium consistent with fibrosis and ventricular remodeling. Mild papillary muscle remodeling. The right ventricle is subjectively normal in size and morphology. There is no left atrial enlargement present. No right atrial enlargement present. Normal RVOT velocity. Systolic anterior motion (SAM) of the mitral valve present, with an elevated dynamic LVOT velocity (not captured on Spectral doppler). There is moderate eccentric mitral regurgitation present secondary to SAM. Normal MR velocity. No other significant valvular regurgitation is present. There is no pericardial effusion noted. No pleural effusion appreciated. No obvious cardiac tumors.

**CARDIAC CHART**

FELINE CARDIAC PARAMETERS	BODY WEIGHT (kg)	HR (BPM)	IVSd (cm) <small>(Moise, Pipers)</small>	LVIDd (cm) <small>(Moise, Pipers)</small>	LVWd (cm) <small>(Moise, Pipers)</small>	FS (%)	EF (%)
NORMAL PARAMETER	-----	150-240	0.35-0.55	<2 <small>(mean 1.5)</small>	3.5-0.55	35-67	80-100
PATIENT	5.6	169	0.61	1.2	0.69	76	98
FELINE CARDIAC PARAMETERS	LA/AO <small>(Boon)</small>	LA/AO HEART BASE (Swe) <small>(Abbott)</small>	LA 2D short axis Base view (cm) <small>(Abbott)</small>		LVOT VEL <small>(m/s)</small>	RVOT VEL <small>(m/s)</small>	E max <small>(m/s)</small>
NORMAL	<1.5	<1.3	<1.2		<1.6	<1.3	<0.9
PATIENT	1.3	1.1	1.2		1.3	0.63	NM

*\*Note: All measurements based upon multi-modal images and methods. An average value is reported.*  
 Adapted from June Boon, Veterinary Echocardiography, 1998  
 Abbott J & MacLean H JVIM 2006;20: 111-119, Moise et al. Am J Vet Res 47:1476, 1986. Pipers et al. Am J Vet Res 40:882, 1979.

**INTERPRETATION OF THE FINDINGS & FURTHER RECOMMENDATIONS**

The diagnosis is hypertrophic obstructive cardiomyopathy (HOCM). This indicates LV thickening (mild in this case) with a dynamic LVOT obstruction (SAM) and secondary mitral regurgitation as the cause of the heart murmur. The hypertrophy and obstruction are both mild. There is no left atrial enlargement present, indicating the risk of spontaneous CHF and/or a thrombotic event is currently low. No additional issues are identified.

While no medications have been shown to definitively alter long term outcome at this stage of disease, atenolol is often initiated to decrease the outflow obstruction. If the patient is easily medicated, it is reasonable to initiate at this time as below. If there is difficulty medicating at home, an alternative approach would be closely monitoring for progression in the next 6-12



**PATIENT**

Pudding Horky

months. Discussion with the owner is advised. No additional medications are indicated prior to significant atrial dilation.

**SPECIES**

Feline

Monitor at home for any respiratory signs or blood clot events (neurologic change, paralysis, etc.). Anesthetic risk is considered mild, however judicious IV fluid rates are advised to avoid fluid overload. Additionally, drugs that stimulate heart rate should be avoided unless clinically necessary (ketamine, glycopyrrolate, atropine).

**BREED**

DSH

**Risk for steroid use typically follows left atrial dilation, which in this case is low. That being said, any cat can experience acute intolerance and close monitoring of RR/RE is recommended, particularly during the initiation phase.**

**SEX**

Male Neutered

**PLAN**

If elected, administer titrating dose of atenolol: 25mg tablets; Give ¼ tab once daily. Recheck heart rate in 1-2 weeks with target stressed rate of 140-160bpm 12-24 hours post-administration. Increase as needed until target reached.

**AGE**

13.6 years

Screening blood pressure and T4 are recommended every 6 months.

**WEIGHT**

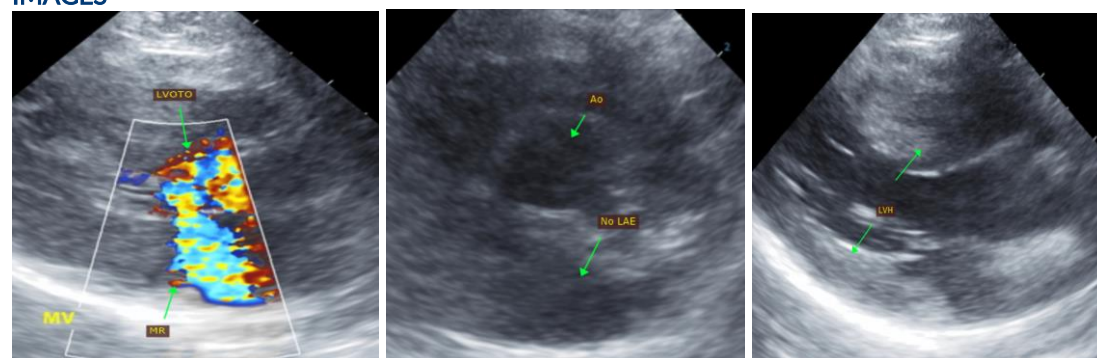
12.4lbs

Recommend recheck echocardiogram in 6 months to assess for progression, sooner if clinical issues arise.

**IMAGES**

**INTERPRETED BY**

Maggie Machen Lamy,  
DVM, DACVIM  
(Cardiology)



**IMAGING PERFORMED BY**

Potomac Mobile  
Veterinary Ultrasound

The information and recommendations provided are based on the images presented by the referring veterinarian. No evaluation can be communicated regarding pathology that was not visible in the image/video clips provided.

**HOSPITAL NAME**

Kindness Animal  
Hospital

Thank you for this referral. This report was generated using transcription software, and minor dictation errors may be present. If the clinical or image interpretation does not parallel your findings or if I can be of any further assistance, please contact me.

**REFERRING VET**

Dr. Jarrett

**Maggie Machen Lamy, DVM**  
Diplomate of the American College of Veterinary Internal Medicine (Cardiology)  
info@sonopath.com

**INVOICE**

26802

**DATE**

10/10/22